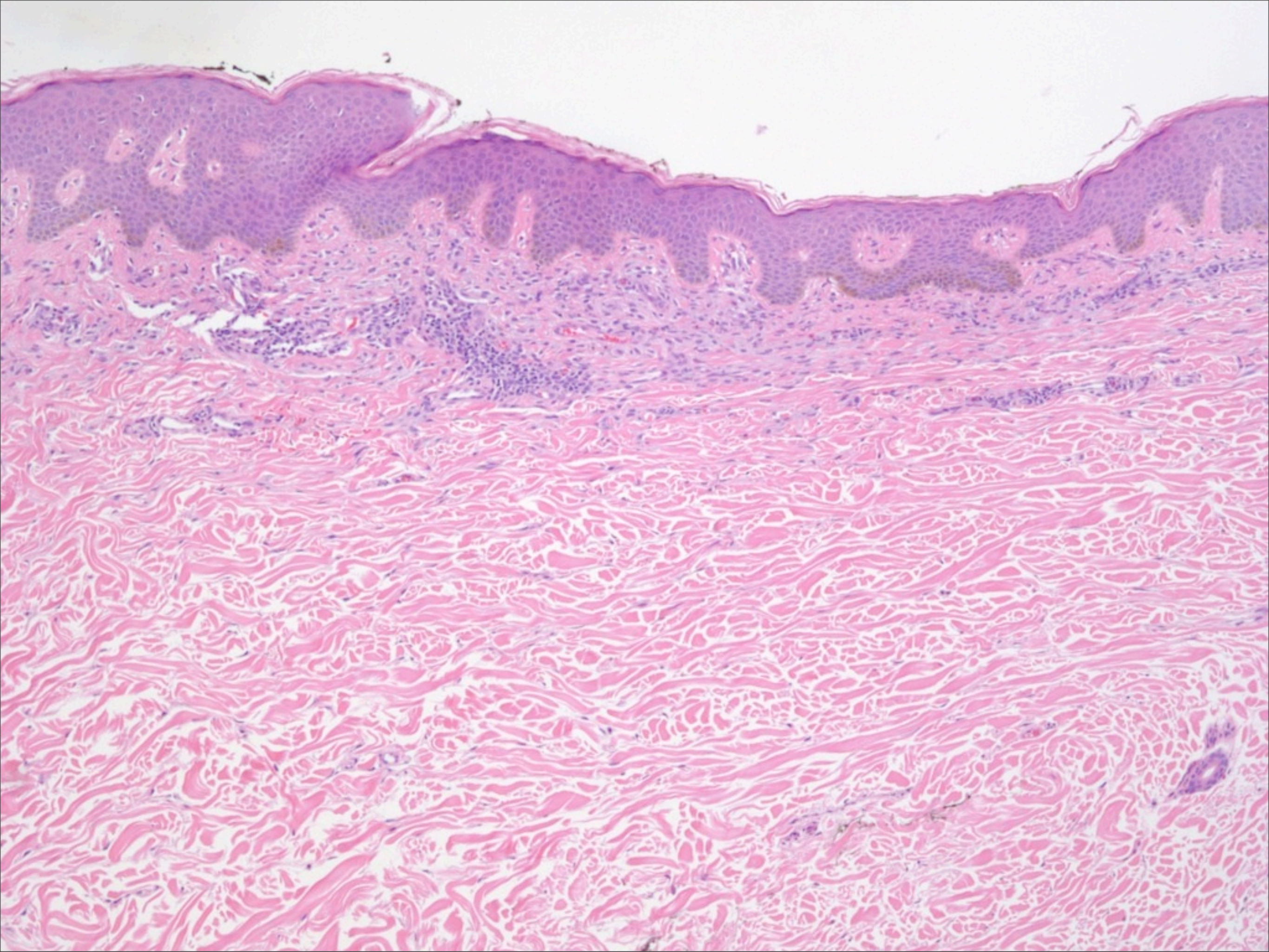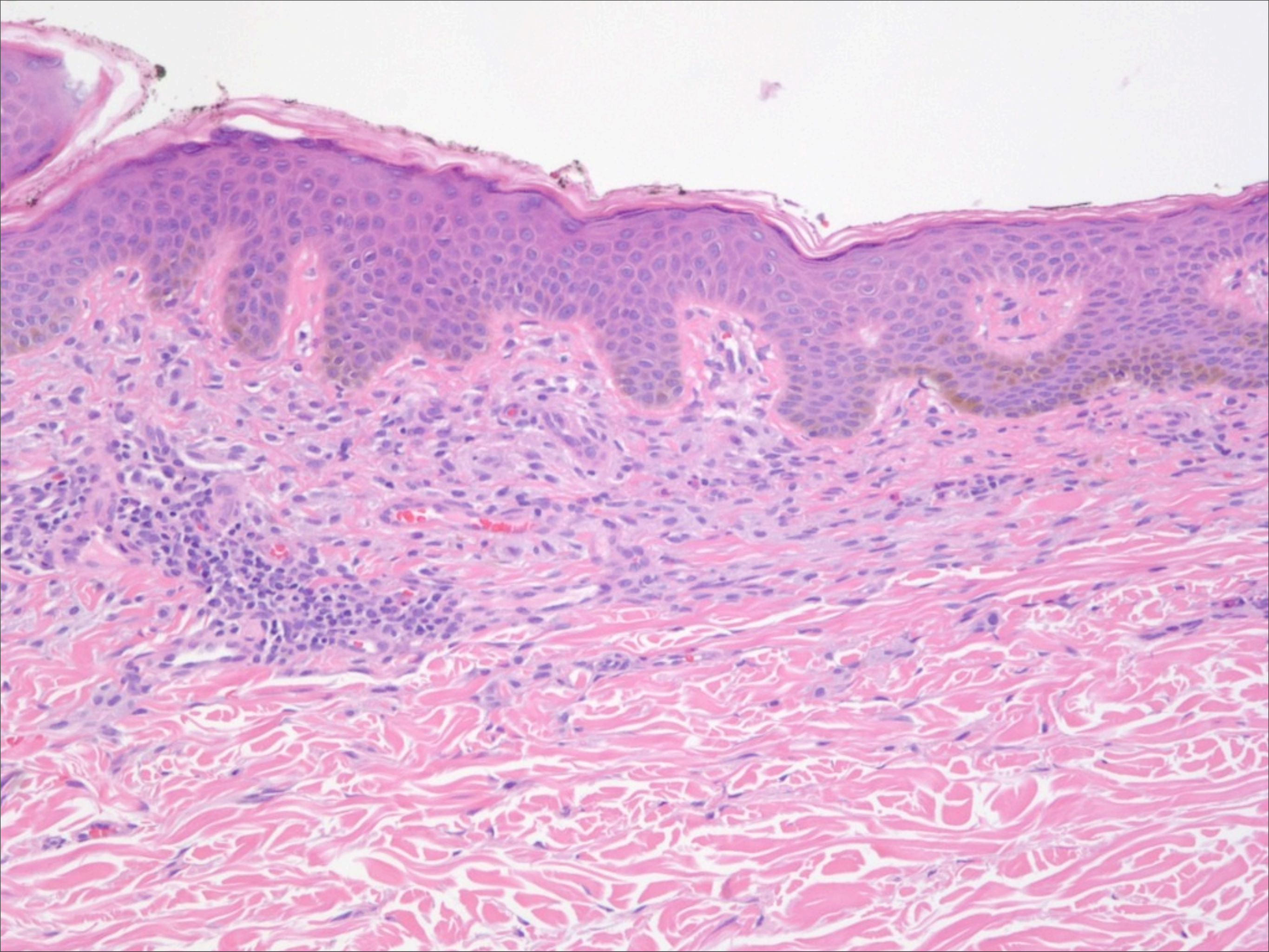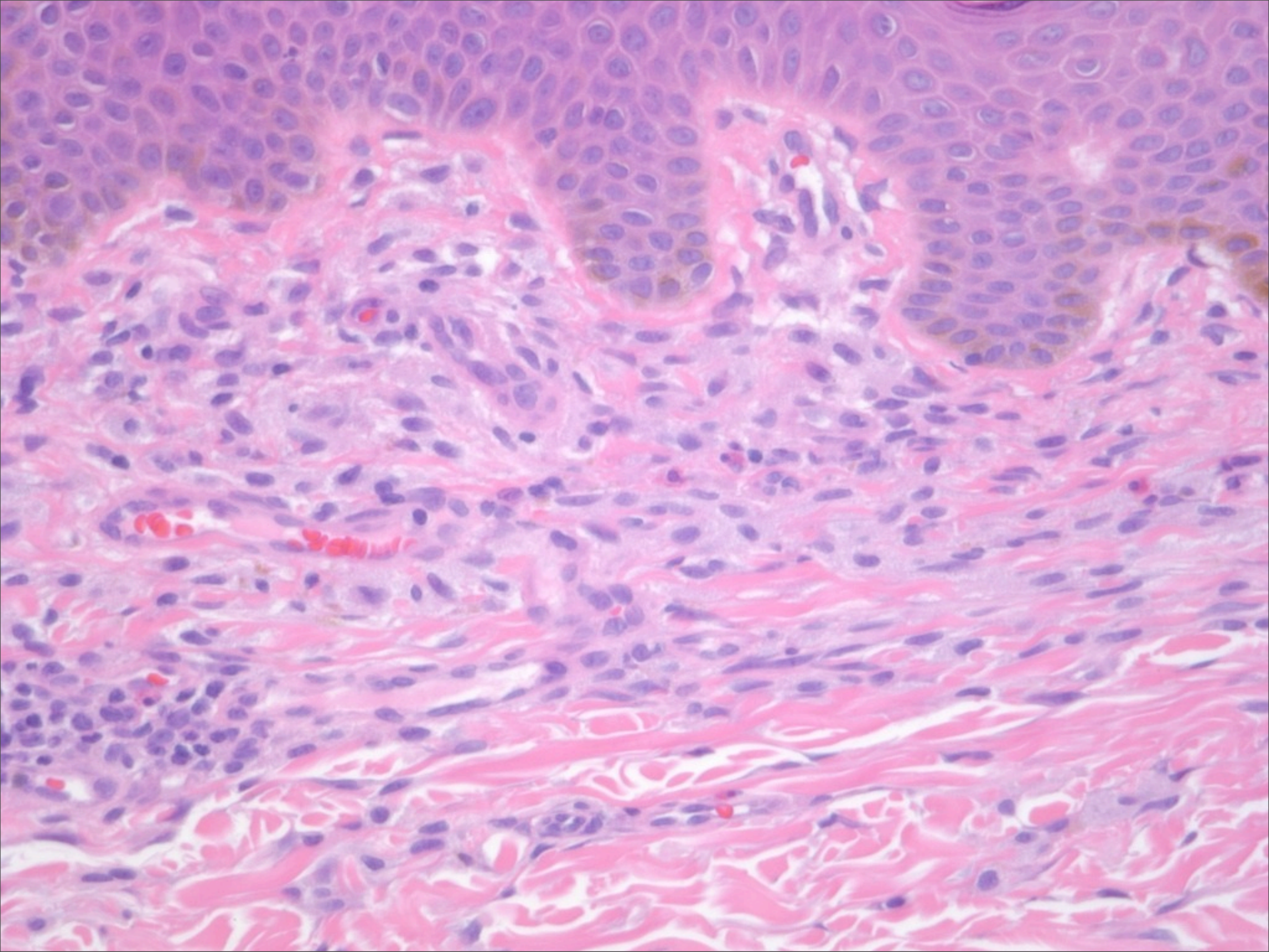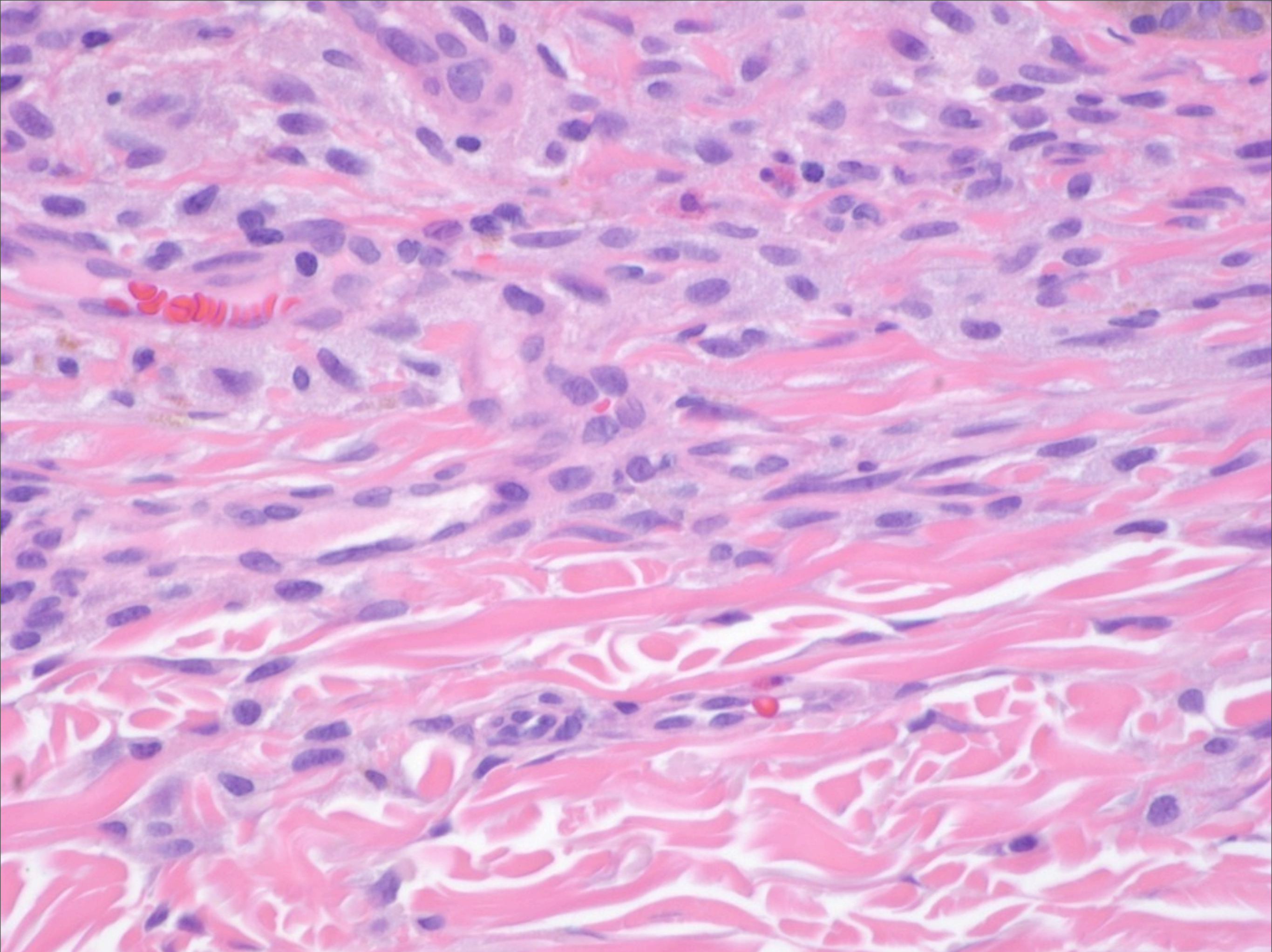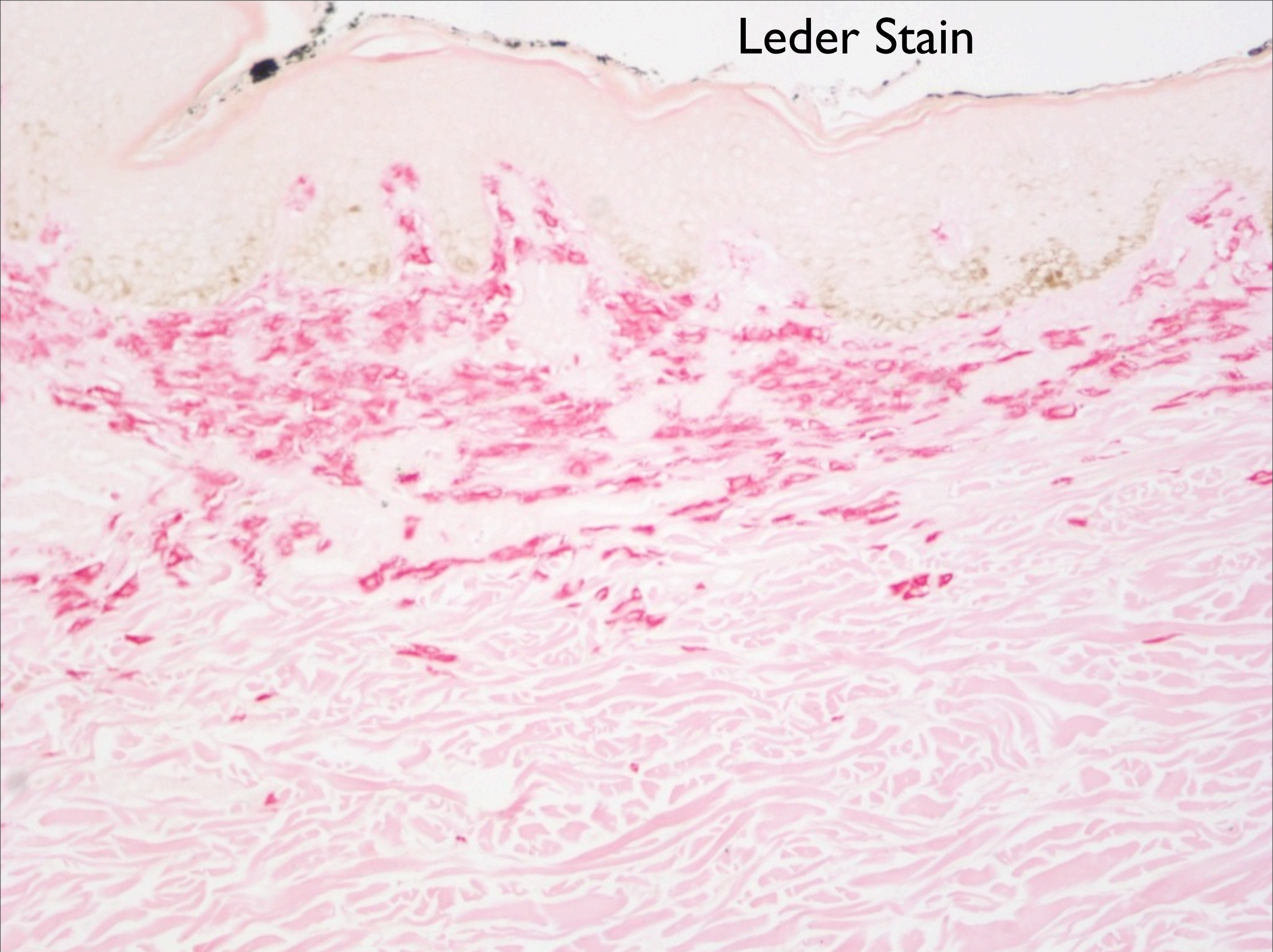




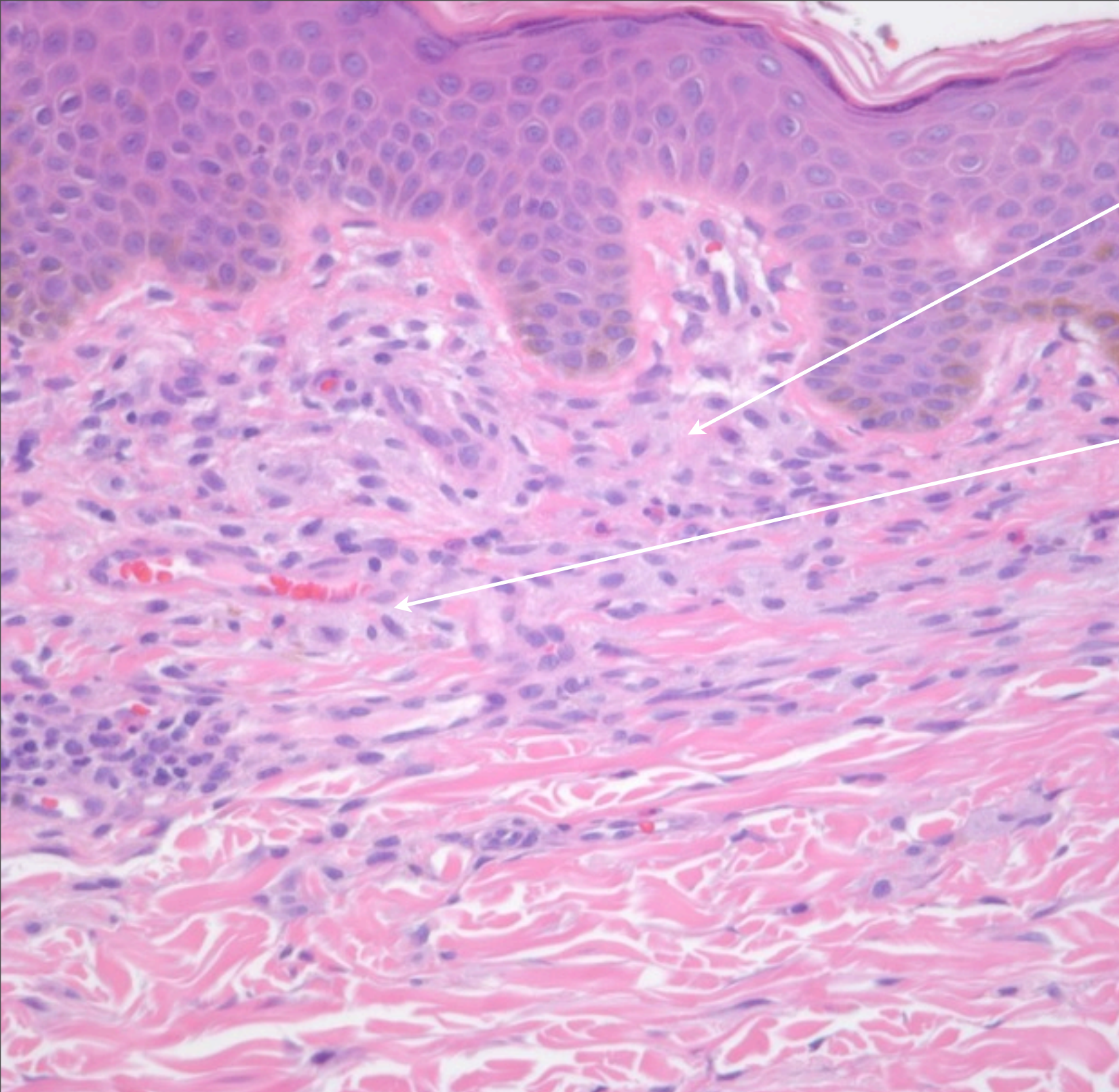
# Leder Stain





# Telangiectasia Macularis Eruptiva Perstans





Mast Cells

Telangiectasia

Eosinophils frequently present